

# Side Effects With a Focus on Lymphadenopathy Following COVID-19 Vaccination in Pediatric and AYA Oncology Patients

Jennifer A. Belsky, DO, MS,\*†‡ Whitney R. Carroll, MS2,§  
Guang Xu, PhD,§ and Seethal A. Jacob, MD, MS\*†

**Summary:** The Coronavirus Disease 2019 (COVID-19) pandemic led to the swift development of multiple vaccinations. Vaccine side effects were well-documented in the healthy adult cohort and included fever and lymphadenopathy, however, side effects in the pediatric immunocompromised population have not been reported. This retrospective study investigated vaccine-eligible children and adolescent young adult oncology patients 12 to 35 years old. We found uncommon, mild, and self-limiting side effects among pediatric cancer patients and survivors. This data will help guide pediatric and AYA oncologists in providing anticipatory guidance and serve as a guide to managing lymphadenopathy as a potential confounder of malignancy.

**Key Words:** pediatric oncology, supportive care, COVID-19, vaccination

(*J Pediatr Hematol Oncol* 2023;45:88–90)

## BACKGROUND

The Coronavirus Disease 2019 (COVID-19) pandemic saw rapid availability of multiple vaccines approved for use in adults and children 12 years old or older.<sup>1</sup> Of importance, in healthy adults, data from all 3 available vaccines (Pfizer-BioNTech, Moderna, and Johnson & Johnson (J&J)) demonstrated concern for lymphadenopathy (0.4–8.4%) and fever (4.7%), which have been attributed to locally activated antigens migrating to draining lymph nodes.<sup>2–4</sup> Similar rates have been reported in children 12 years and older.<sup>4</sup>

Adenopathy was reported as an unsolicited event in 1.1% of patients receiving the Moderna vaccine. “Axillary swelling or tenderness” was listed separately and occurred in up to 16.0% of patients 18 to 64 years of age and up to 8.4% of patients over 65 years of age (vs. 4.3% and 2.5% in the corresponding placebo groups, respectively). Patients receiving the Pfizer-BioNTech vaccine had a self-reported rate of adenopathy of 0.3%. Clinically, axillary swelling or

adenopathy manifested within 2 to 4 days after either dose and lasted on average 1 to 2 days (Moderna) and 10 days (Pfizer-BioNTech). Among all study vaccine recipients in the Pfizer-BioNTech group, 4.7% of patients 18 to 55 years old experienced a fever  $\geq 38^{\circ}\text{C}$ . In addition, myocarditis and pericarditis have been observed.<sup>4,5</sup>

With the overwhelmingly positive protective effects of the vaccine, there are some unintended side effects and hesitations in the general population, as well as the immunocompromised patient population. It remains unclear what proportion of oncology patients will experience a vaccine side effect, including adenopathy on imaging, whether the rate of adenopathy will vary between different doses and unique vaccines, the size, number, laterality, and morphology of affected lymph nodes, or how long nodes will remain abnormal in an appearance on various imaging modalities. Findings may be present for a longer period on higher sensitivity imaging such as  $^{18}\text{F}$ FDG PET (PET), in which inflammatory activity may be detected even in nonenlarged nodes. In addition, febrile neutropenia is a serious complication for patients on therapy that has the potential for hospitalizations, intravenous antibiotic administration, and burden for patients and hospitals. To best counsel families on expectations surrounding the vaccine, data regarding the risk of side effects must be available.

Considering these preliminary findings, it is unknown if children and adolescents and young adults (AYA) with cancer and altered immune function will have similar side effects. This retrospective study aimed to explore and describe the side effects of the COVID-19 vaccine in the pediatric and AYA oncology population.

## MATERIALS AND METHODS

### Study Design and Patient Selection

We performed a retrospective chart review of oncology patients at Riley Hospital for Children and Indiana University Health who received at least 1 dose of the COVID-19 vaccine from March 2021 to August 2021 with an active or previous oncology diagnosis, treated on a pediatric oncology protocol. All patients cared for at these 2 sites who met the following were included: (1) 12 years of age or older to 35 years or younger of age, (2) received any COVID-19 vaccination (Moderna, Pfizer, or J&J), and (3) had an active or previous oncology diagnosis. At the time of this manuscript, only the Pfizer vaccine was available for children older than 12 years of age. Patients who received a COVID-19 vaccine outside the state of Indiana were exempt. Data was collected and reviewed from the initial COVID-19 vaccination date through 8 weeks following each vaccination, including prior COVID-19 testing. This

Received for publication December 14, 2021; accepted December 13, 2022.

From the \*Department of Pediatrics, Indiana University School of Medicine; †Division of Pediatric Hematology Oncology, Riley Hospital for Children; ‡Division of Pediatrics, Indiana University College of Medicine; and §Marian University College of Osteopathic Medicine, Indianapolis, IN.

Research reported in this publication was supported by the National Heart, Lung, and Blood Institute of the National Institutes of Health under Award Number K23HL143162. The content is solely the responsibility of the authors and does not necessarily represent the official views of the National Institutes of Health.

The authors declare no conflict of interest.

Reprints: Jennifer A. Belsky, DO, Division of Pediatric Hematology Oncology, Riley Hospital for Children, 705 Riley Hospital Drive, Indianapolis, IN 46202 (e-mail: jbelksy@iu.edu).

Copyright © 2023 Wolters Kluwer Health, Inc. All rights reserved.

DOI: 10.1097/MPH.0000000000002621

study was exempted from the institutional review board at Indiana University.

## Procedures and Statistical Design

We obtained demographics, clinical symptoms, laboratory and imaging results, hospitalizations, and outcomes data from each patient's electronic medical record. Clinical outcomes were followed up to 8 weeks after the last COVID vaccine was given. Our institution's COVID-19 vaccination guidelines followed recommendations outlined by the Centers for Disease Control, which recommended vaccination for all immunocompromised patients.<sup>5</sup> Vaccination records for this study were obtained through the Children and Hoosier Immunization Registry Program (CHIRP), Indiana's online vaccination database, and confirmed with the electronic medical record. Patients without a confirmed immunization history were excluded. The means, medians, SDs, and confidence intervals of quantitative demographic variables, such as patient ages, were analyzed using GraphPad Prism (v9.2.0). Categorical data such as race, gender, diagnosis, therapies, vaccine status, and side effects were counted, and the proportions of those were calculated and presented in percentage.

## Observations

We identified 122 unique patients who received a COVID-19 vaccination over the study period (Table 1). More than half of the patients were male (n=86, 55.7%) with a median age of 18 years (range: 12-30 y). All 3 vaccine options were administered (Pfizer n=102, Moderna n=17, J&J n=3), and 98.4% (n=120) of patients completed the primary vaccination series. Among these patients, 34.4% (n=42) were actively receiving chemotherapy or within 9 months of receiving intensive chemotherapy. Of patients receiving leukemia therapy, the majority were in maintenance therapy (n=7, 87.5%).

Of the 122 patients who received the vaccine, 3 unique patients (2.5%) had a reported reaction. Of patients who had a reaction, all patients were white, male, had no prior COVID infection, and received the Pfizer vaccine. Side effects were reported <24 hours of receiving the vaccine and resolved without intervention in <48 hours. No patients were hospitalized for fever and neutropenia or additional COVID-19 vaccine-related symptoms.

We identified 47 (38.5%) patients who underwent imaging as part of their routine treatment or surveillance, including CT (n=16), magnetic resonance imaging (n=14), ultrasound (2), and radiograph (15), with only 1 patient found to have incidental lymphadenopathy (Fig. 1).

Of the 2 patients with lymphadenopathy, Patient 1, who self-reported ipsilateral axillary lymphadenopathy, was 9 months postcompletion of anaplastic large cell lymphoma chemotherapy and presented 6 weeks after receiving the second Pfizer vaccine. CT with contrast was concerning for a 5.0×3.0 cm axillary lymph node ipsilateral to vaccine administration. The suspicious lymph node was biopsied, and pathology was consistent with relapsed anaplastic large cell lymphoma.

Patient 2, with lymphadenopathy found incidentally on routine CT with contrast imaging as part of treatment surveillance, was 3 months postchemotherapy for Hodgkin lymphoma. Imaging characteristics included a new right axillary lymph node measuring 1 cm with enlarged sub-centimeter bilateral axillary lymph nodes and a small 1 mm right upper lobe lung nodule (Fig. 1A). Follow-up <sup>18</sup>FDG PET/CT scan 4 weeks later showed improvement of lymphadenopathy

**TABLE 1.** Patient Characteristics and Side Effects Following COVID-19 Vaccine Administration

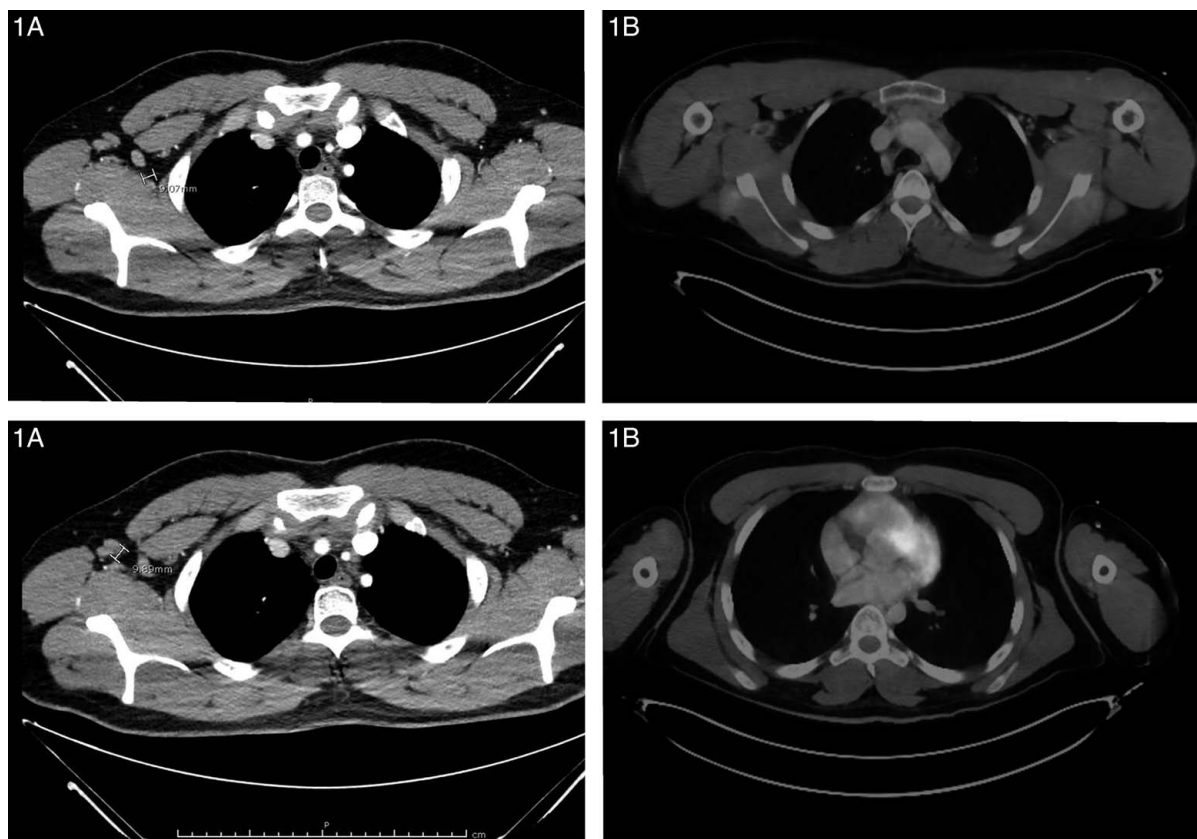
Cancer Cohort	
Characteristic	N (%)
Unique patients	122
Male Sex	68 (55.7)
Median age in years (range)	18 (12-30)
Race/Ethnicity	
White	112 (91.8)
Asian	5 (4.1)
Black	4 (3.3)
Pacific islander	1 (0.8)
Hispanic/Latino	10 (8.2)
Non-Hispanic/Latino	112 (91.8)
Type of Cancer	
Solid tumor	33 (27.0)
Leukemia	25 (20.1)
Central nervous system	25 (20.1)
Lymphoma	22 (18.0)
Reported side effects within 8 wk	
Numbness	2 (1.6)
Fever	1 (0.82)
Chills	1 (0.82)
Myalgia	1 (0.82)
Headache	1 (0.82)
Lymphadenopathy	1 (0.82)
Routine surveillance imaging	47 (38.5)
Incidental lymphadenopathy	1 (0.82)

with Deauville 2 score, consistent with prior scarred lymph nodes at the end of therapy (Fig. 1B), and complete resolution of his previously identified lung nodule.

## CONCLUSIONS

The results of this cohort study suggest the majority of pediatric and AYA oncology patients 12 years of age or older had few side effects following COVID-19 vaccination. Those who did, reflected what has been reported in the general adult population, with a lower incidence of reported and imaging-confirmed lymphadenopathy.

Children with cancer are prone to severe COVID-19 infections,<sup>6</sup> and oncologists hesitant to recommend the COVID-19 vaccination to patients both on and off therapy should be aware of the expected post-vaccine course to appropriately guide patients and families.<sup>7,8</sup> Our retrospective review identified rare, mild, and self-limiting side effects without evidence of increased fever and neutropenia complications following the COVID-19 vaccine. As febrile neutropenia remains a serious complication for patients on therapy that leads to hospitalization, intravenous antibiotic administration, and burden for patients and hospitals, it is a reassuring finding in this cohort. In addition, we did not detect a higher incidence of symptomatic lymphadenopathy, which may provide reassurance to families struggling with vaccine hesitancy. Vaccine clinical trials are currently underway for children younger than 5 years old, with little published data surrounding side effects in the eligible pediatric oncology population. A limitation of this study is its retrospective nature, with a small sample size. In addition, this paper focuses on short-term clinical responses, while future research must address the immunologic response level in pediatric oncology patients. Future studies must focus on larger, prospective studies investigating side effects and incidental lymphadenopathy to better guide



**FIGURE 1. Lymphadenopathy imaging findings post-COVID-19 vaccination.** 1A, Initial CT Chest with Intravenous Contrast 36 hours post-COVID-19 vaccination. New right axillary lymph node measuring 1 cm. Additionally enlarged sub-centimeter right and left axillary lymph nodes. New tiny 1 mm right upper lobe lung nodule. 1B, Follow-up  $^{18}\text{F}$ FDG PET/CT scan 4 weeks post-COVID-19 vaccination. Mildly FDG avid bilateral axillary lymph nodes, likely reactive. No FDG pulmonary nodule was identified. Overall Deauville score 2.

clinicians in counseling regarding COVID-19 vaccination in children and AYAs with cancer.

## REFERENCES

1. Krammer F. SARS-CoV-2 vaccines in development. *Nature*. 2020;586:516–527.
2. Mehta N, Sales RM, Babagbemi K, et al. Unilateral axillary Adenopathy in the setting of COVID-19 vaccine. *Clin Imaging*. 2021;75:12–15.
3. Tu W, Gierada DS, Joe BN. COVID-19 vaccination-related lymphadenopathy: What to be aware of. *Radiol Imaging Cancer*. 2021;3:e210038.
4. Local Reactions, Systemic Reactions, Adverse Events, and Serious Adverse Events: Pfizer-BioNTech COVID-19 Vaccine. Accessed December 12, 2021. 2021. <https://www.cdc.gov/vaccines/covid-19/info-by-product/pfizer/reactogenicity.html>
5. COVID-19 Vaccines are Effective. 2021. Accessed December 25, 2021. <https://www.cdc.gov/coronavirus/2019-ncov/vaccines/effectiveness/index.html>
6. Belsky JA, Tullius BP, Lamb MG, et al. COVID-19 in immunocompromised patients: a systematic review of cancer, hematopoietic cell and solid organ transplant patients. *J Infect*. 2021;82:329–338.
7. Biswas N, Mustapha T, Khubchandani J, et al. The Nature and extent of COVID-19 vaccination hesitancy in healthcare workers. *J Community Health*. 2021;46:1244–1251.
8. Wolfson S, Kim E, Plaunova A, et al. Axillary adenopathy after COVID-19 vaccine: no reason to delay screening mammogram. *Reig Radiology*. 2022;303:297–299.